

# **MAPCON 2018 E-CASES**

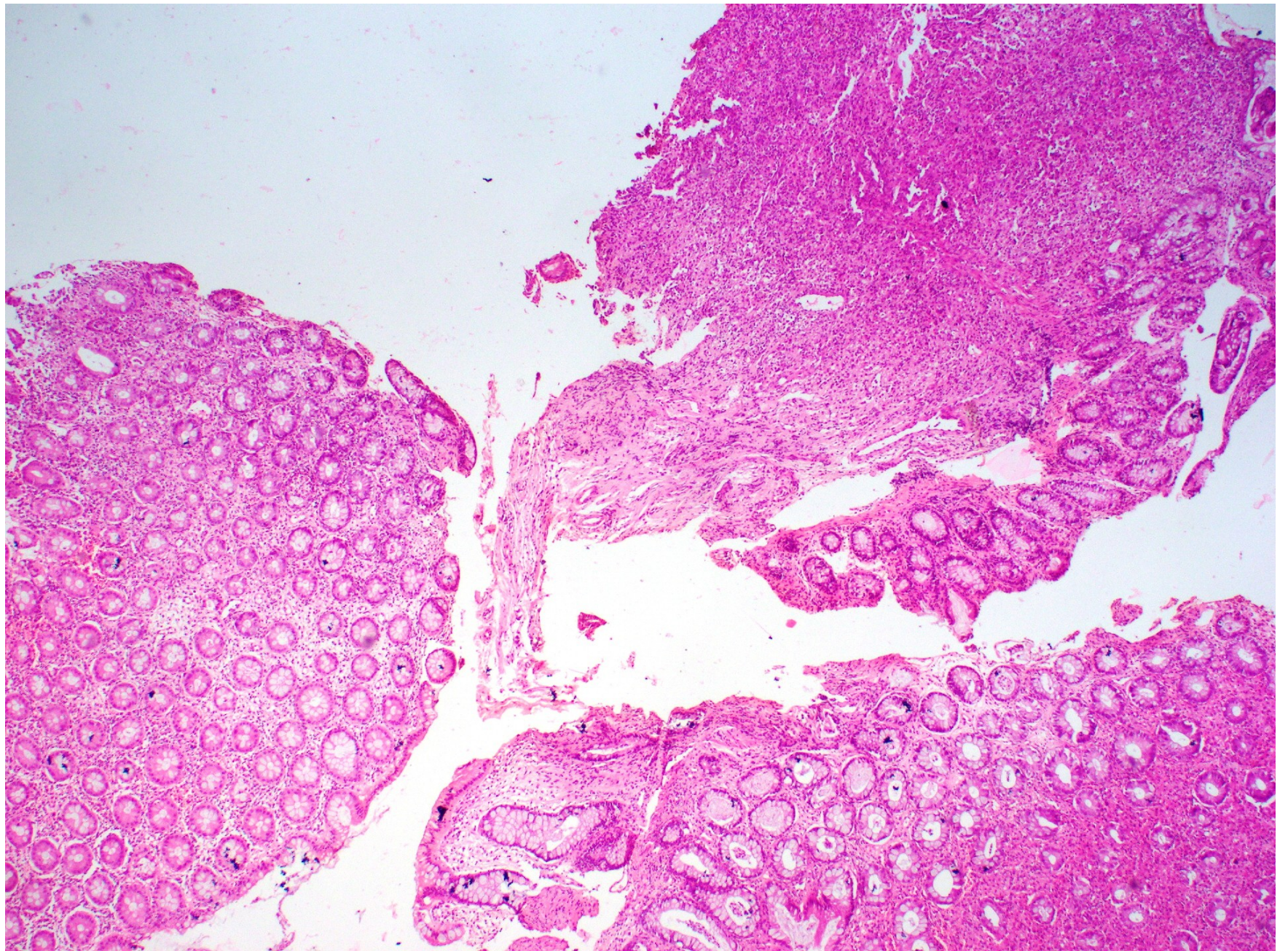
## **E-CASE 05**

Deesha Pathlab, Sangli

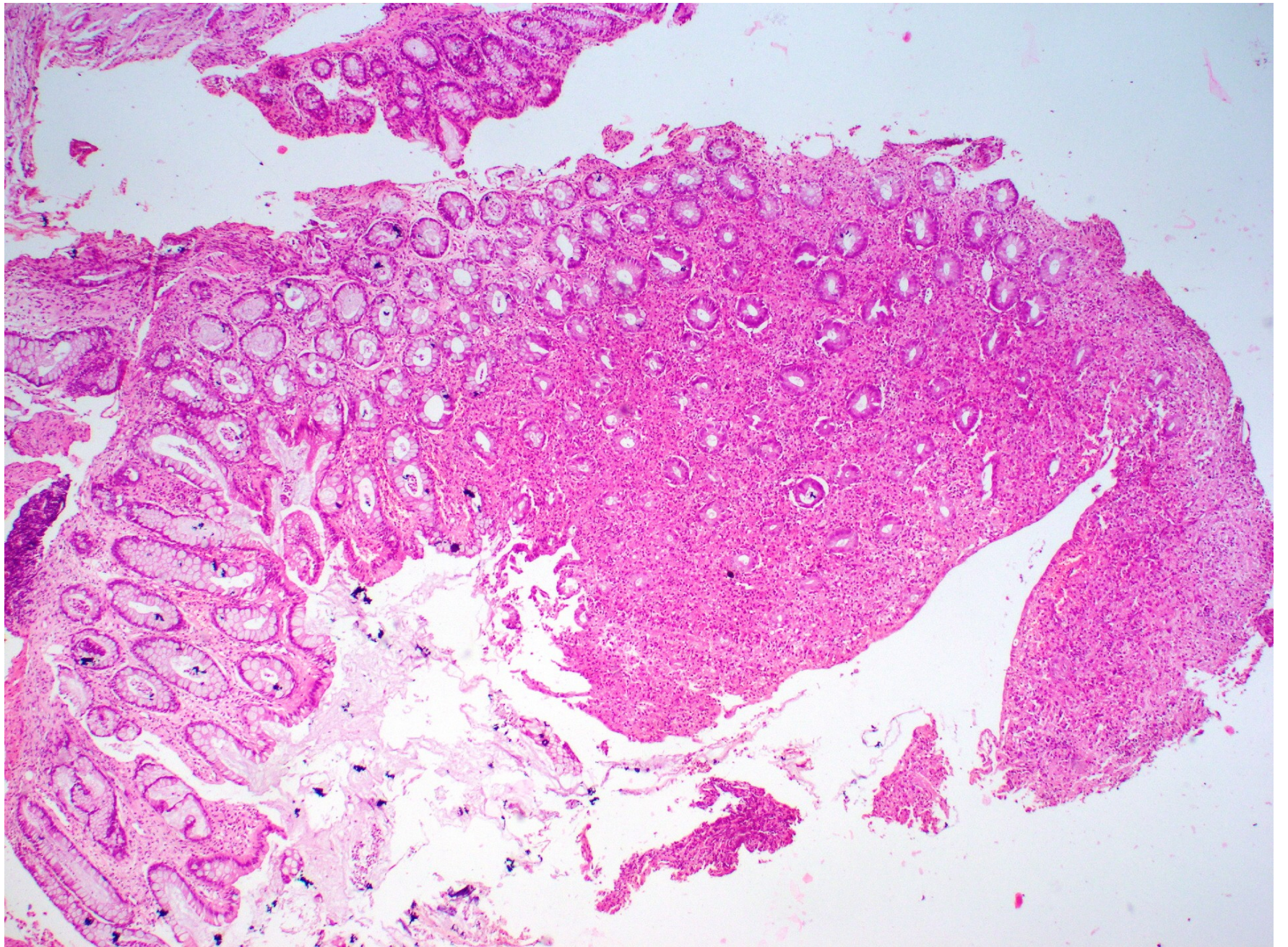
## E-CASE 05

- 5 year old female presented with weight loss and failure to thrive.
- Endoscopy - multiple ulcers in caecum and rectum.
- Biopsy from ulcerative lesions in rectum.

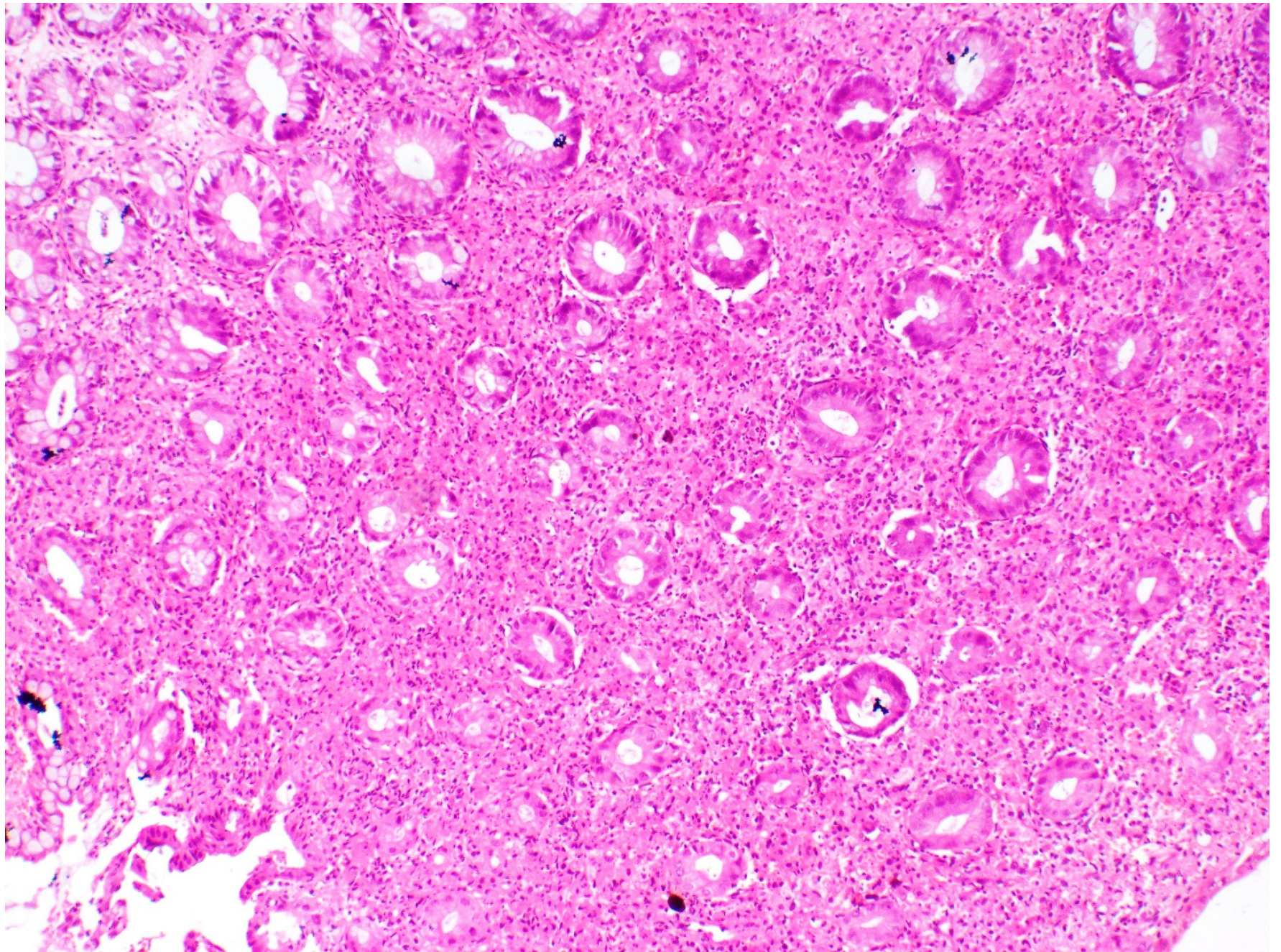




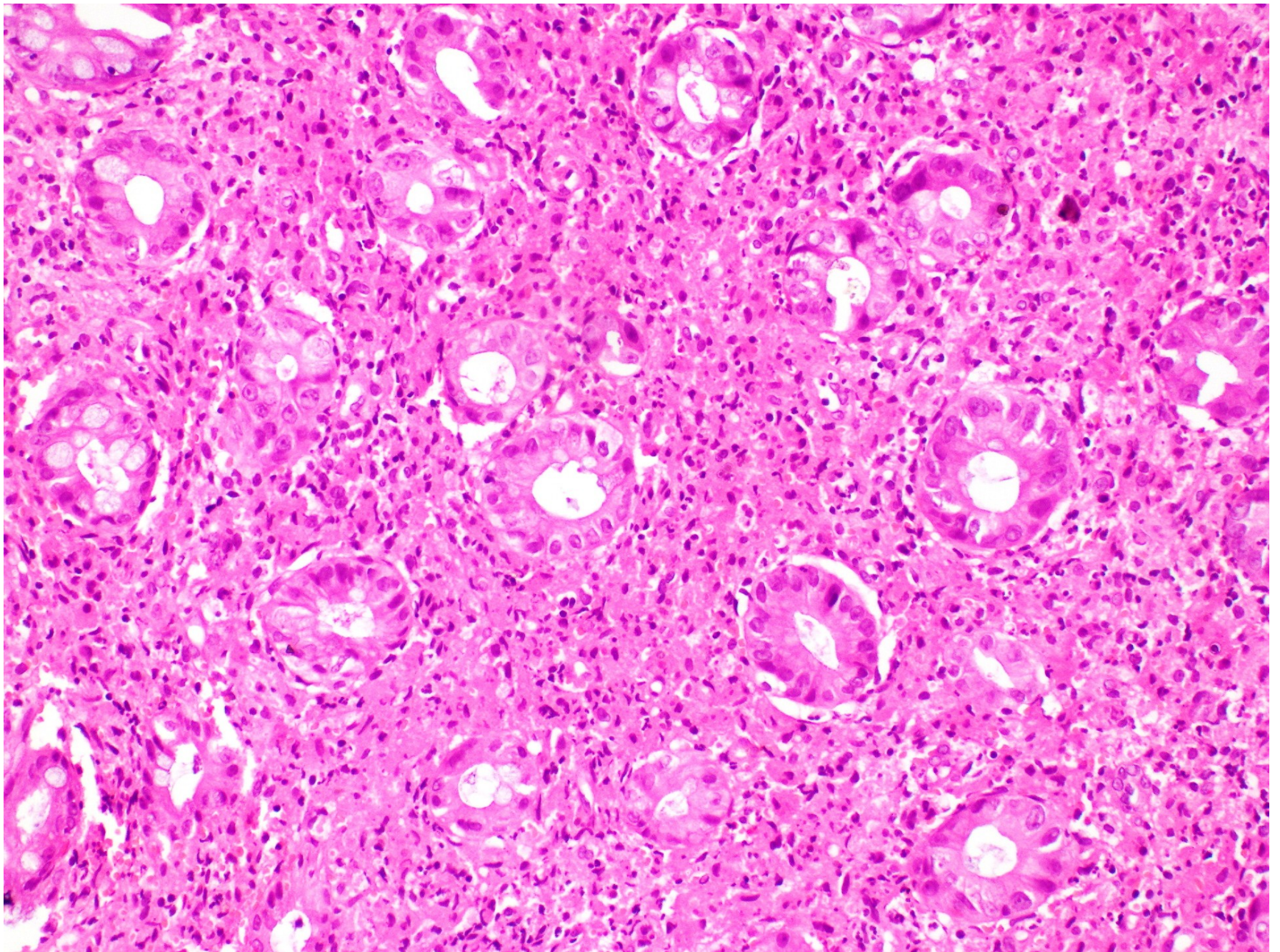




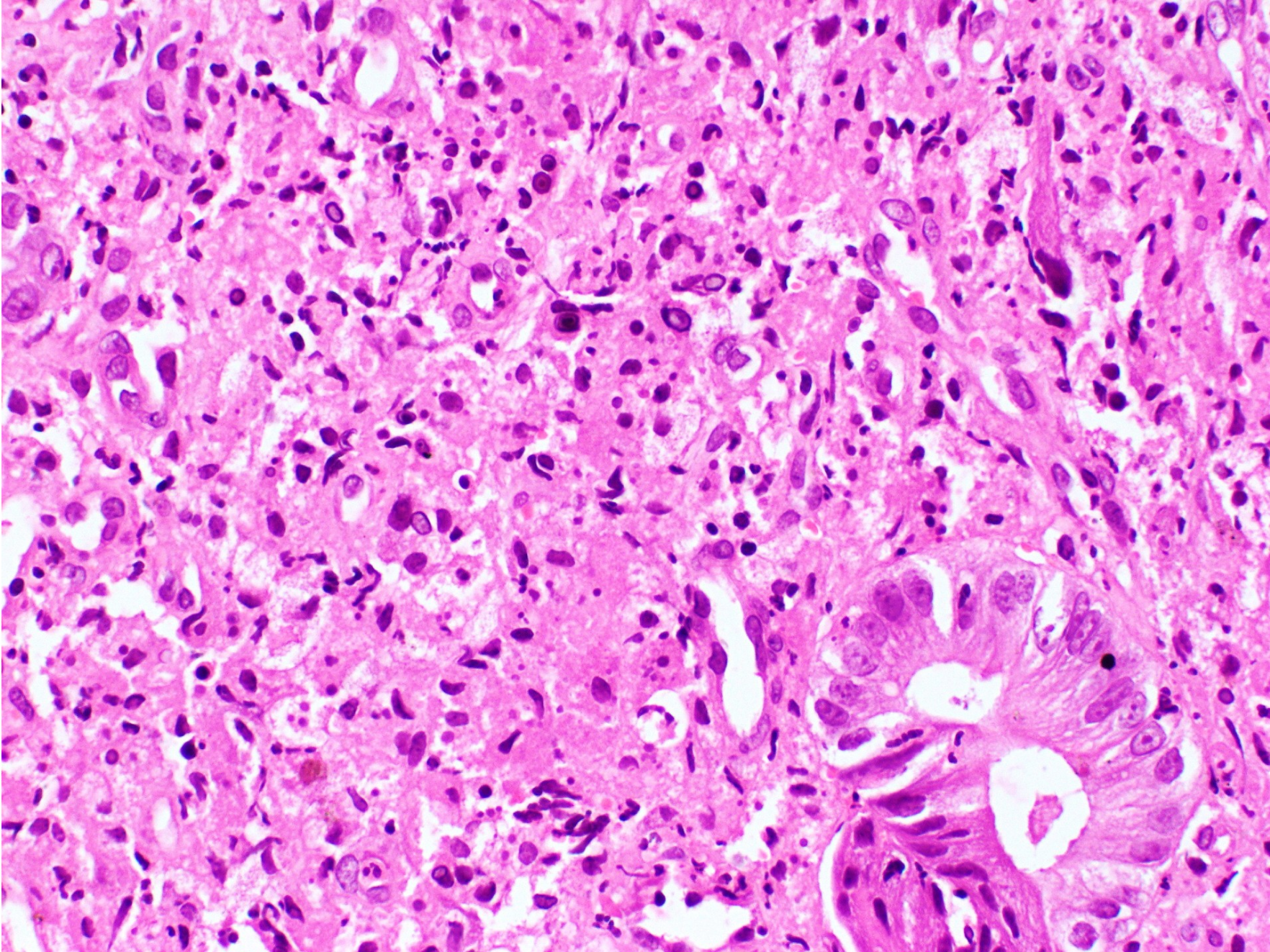




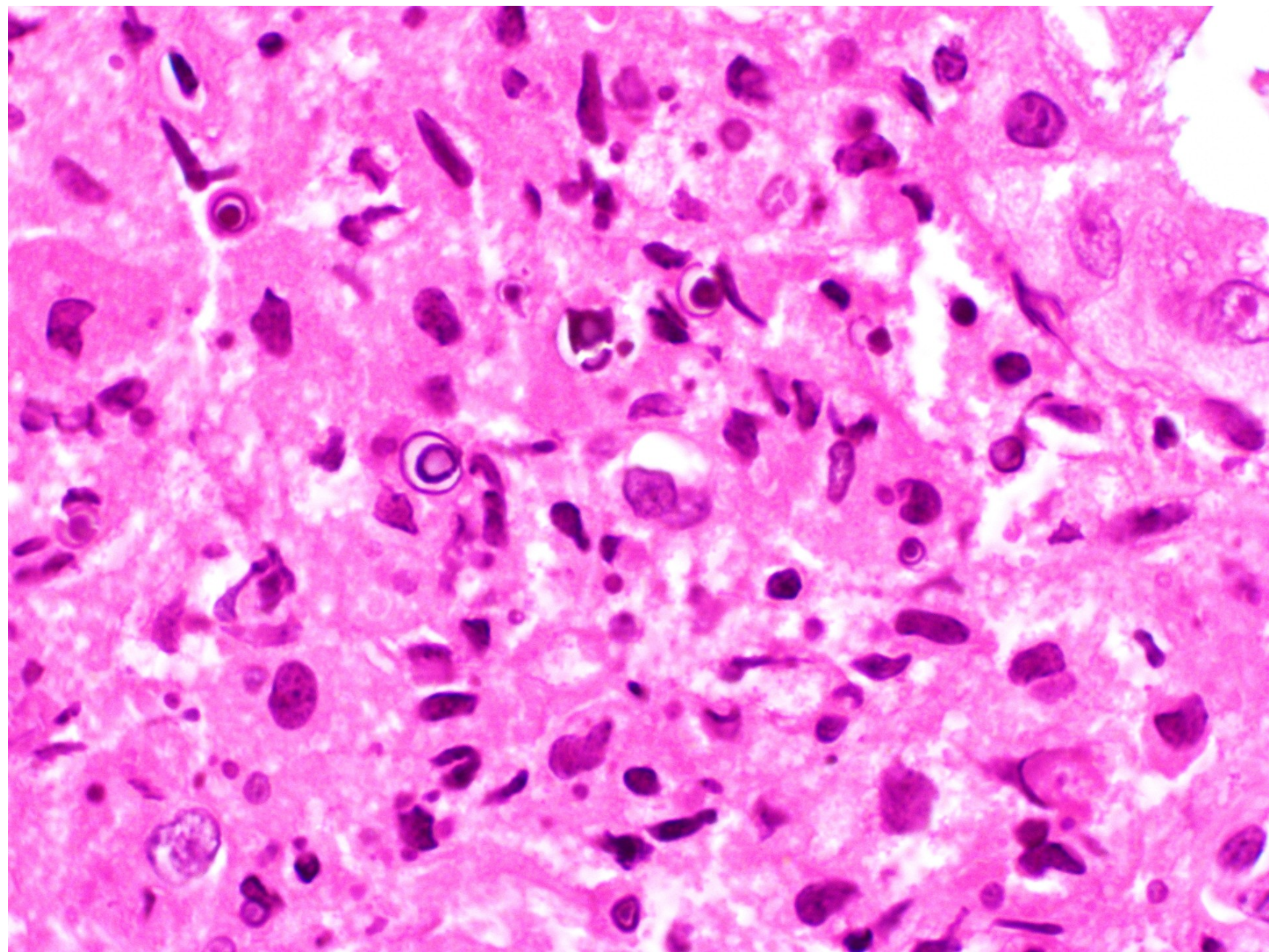




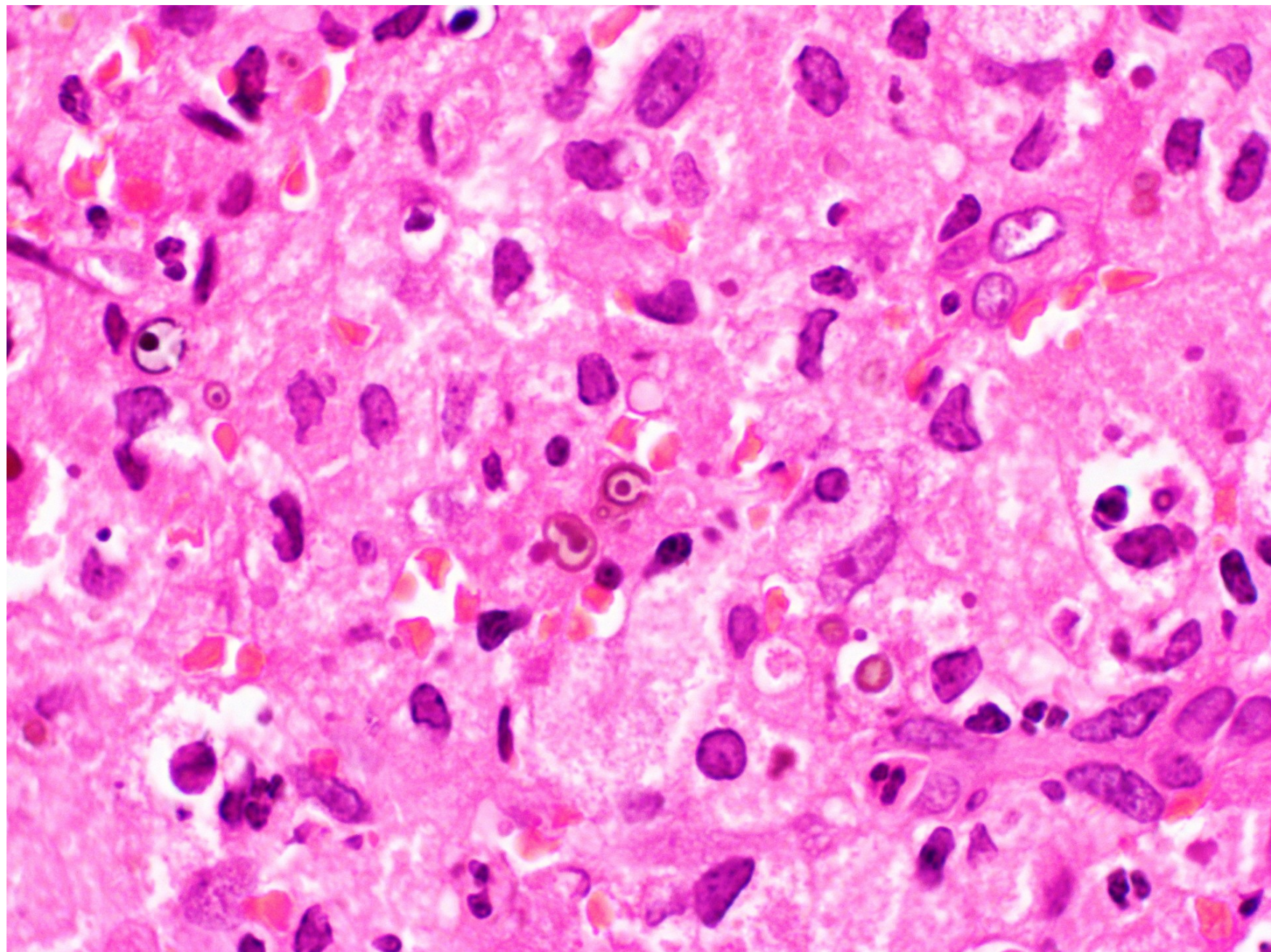




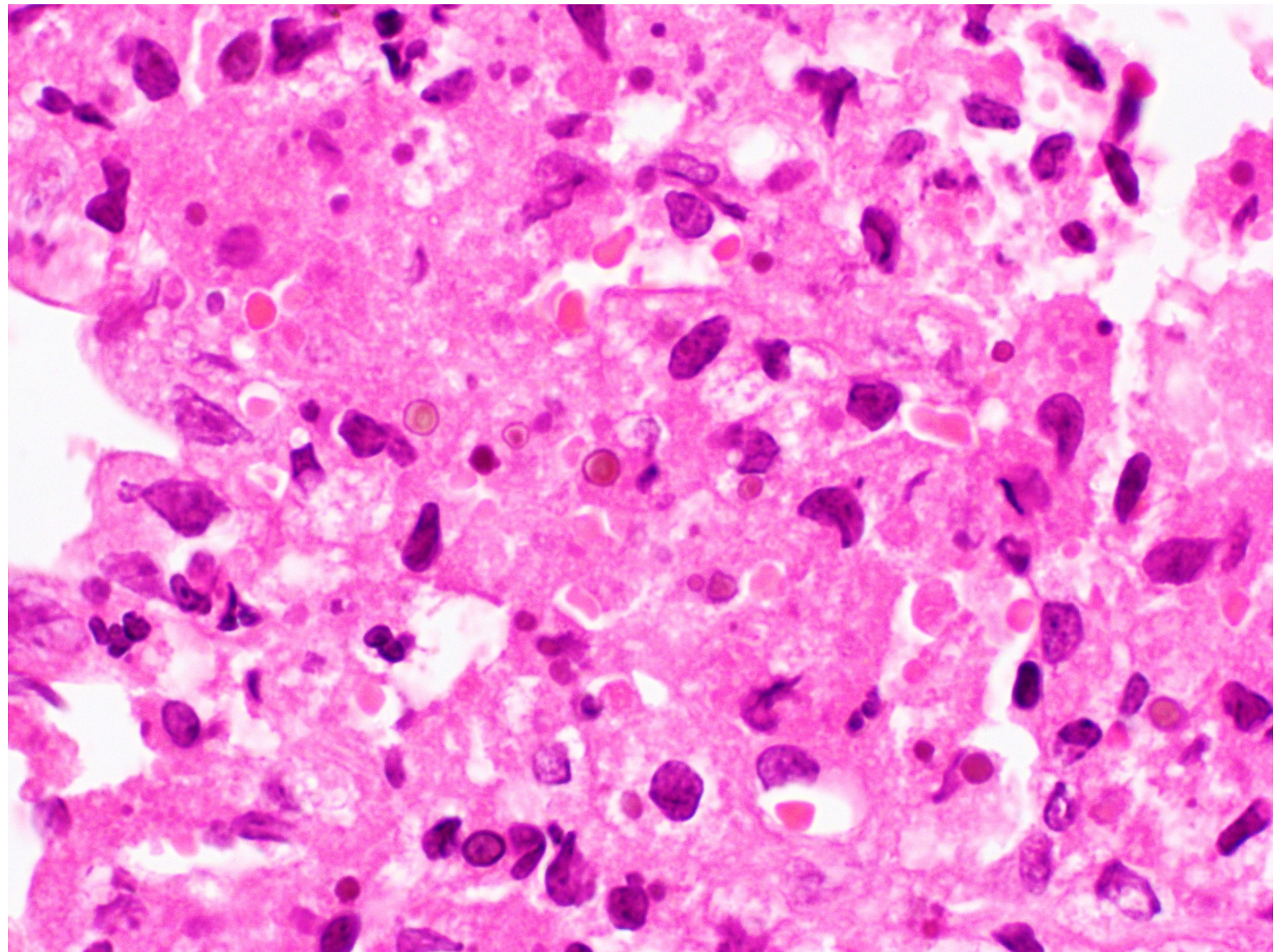




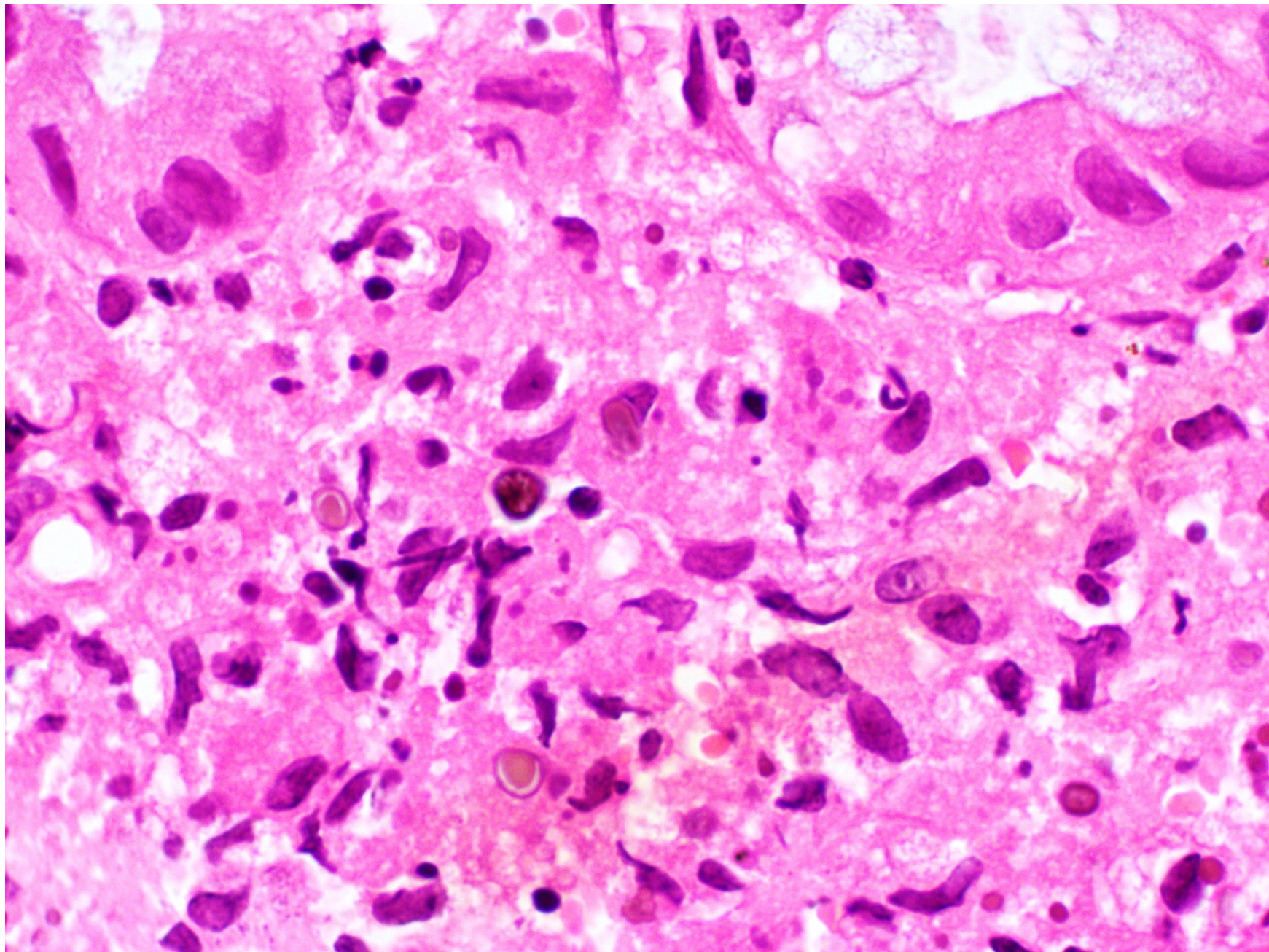














DIAGNOSIS ??